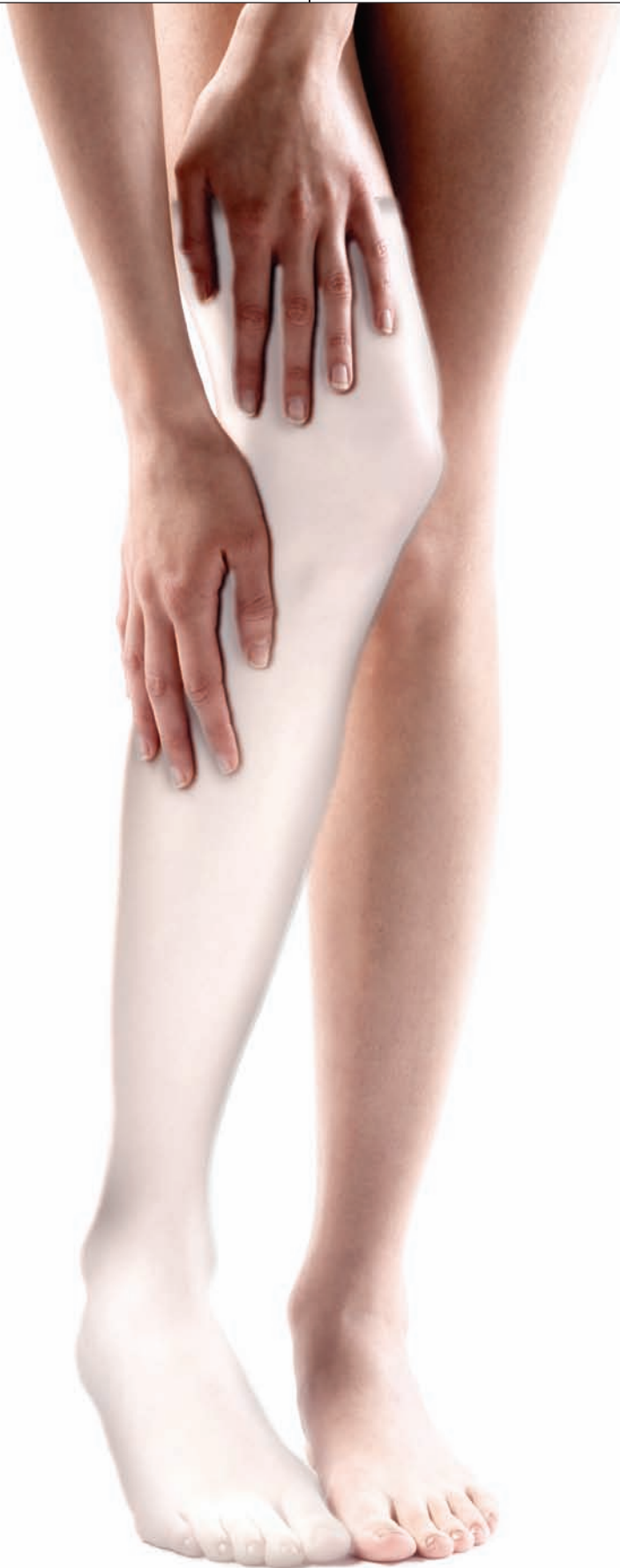



GETTY IMAGES

# Living with *Ghostly* Limbs

Scientists are pinpointing the neurological roots of the vivid and painful illusion of phantom limbs in amputees—and finding ways to curb it

*By Miguel Nicolelis*

One morning in my fourth year of medical school, a vascular surgeon at the University Hospital in São Paulo, Brazil, invited me to visit the orthopedics inpatient ward. “Today we will talk to a ghost,” the doctor said. “Do not get frightened. Try to stay calm. The patient has not accepted what has happened yet, and he is very shaken.”

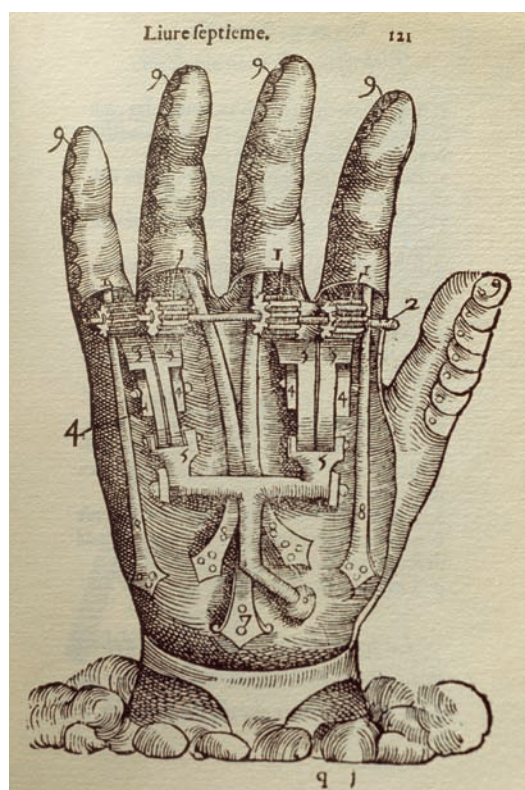
A boy around 12 years old with hazy blue eyes and blond curly hair sat before me. Drops of sweat soaked his face, contorted in an expression of horror. The child’s body, which I now watched closely, writhed from pain of uncertain origin. “It really hurts, doctor; it burns. It seems as if something is crushing my leg,” he said. I felt a lump in my throat, slowly strangling me. “Where does it hurt?” I

asked. He replied: “In my left foot, my calf, the whole leg, everywhere below my knee!”

As I lifted the sheets that covered the boy, I was stunned to find that his left leg was half-missing; it had been amputated right below the knee after being run over by a car. I suddenly realized that the child’s pain came from a part of his body that no longer existed. Outside the ward I heard the surgeon saying, “It was not him speaking; it was his phantom limb.”

At that time, I did not know that at least 90 percent of amputees—millions worldwide—have experienced a phantom limb: the strange and errant feeling that a missing body part is still present and attached to their body. In some cases, the part moves; in others, it is locked in place. Such ghostly appendages are often defined by a diffuse tingling sensation that extends throughout the amputated limb

Artificial articulated hand designed by French military surgeon Ambroise Paré, who described many cases of phantom limbs in soldiers returning from European battlefields in the 1500s. His work was ignored for more than 300 years.



and effectively reconstructs it. These phantoms are often very painful and terrifyingly vivid. In some cases, they endure for years.

Although scientists are still struggling to identify the biological basis for such apparitions, recent research suggests that they are not the product of erroneous neural signals emanating from an amputee's stump. Rather, most neuro-

scientists now believe, they arise largely from activity in networks of neurons distributed throughout the brain. These networks enable a person to create an anatomical image of his or her own body and attach sensations to that body image. Studies of such cerebral representations and how they change after amputation have led to new experimental therapies for phantom limb syndrome.

### Painful Appendages

Scientists, doctors and laypeople have known about phantom limbs for centuries. During the Middle Ages, for instance, European folklore glorified the miraculous restoration of sensation in amputated limbs in soldiers.

In one account, which dates back to the fourth century, twin boys tried to physically reattach limbs onto patients who had lost an arm or leg. The amputees supposedly developed the feeling of the divine presence in the missing part of their body—presumably the result of a phantom. The boys later became official saints of the Catholic Church; amputees who prayed to their memory felt their limbs coming back. In the 1500s French military surgeon Ambroise Paré, whose improved surgical techniques boosted survival for amputees, described many cases of the phenomenon in soldiers returning from European battlefields.

In 1872 American neurologist Silas Weir Mitchell coined the term “phantom limb” to describe the sensations that mutilated Civil War soldiers felt in their lost limbs. Since then, scientists have written up hundreds of case studies, revealing various manifestations. Interviews with amputees suggest that intense limb pain before amputation, say, from a severe fracture, deep ulcer, burn or gangrene, is a major risk factor for developing phantom pain afterward—as if the pain were etched in memory so that it remains even after its source is gone. More than 70 percent of patients find their phantom limbs painful immediately after surgery; in many cases, the pain persists for years.

Phantom limbs sometimes perform phantom movements. Recent amputees may even wake up screaming that their nonexistent leg is “trying to leave the bed on its own to walk around the room.” In one third of afflicted people, however, the absent limb becomes completely paralyzed, often agonizingly so—for instance, embedded in an ice cube, permanently twisted in a spiral or tortuously pinned to the back.

Researchers now know that phantom sensa-

#### FAST FACTS

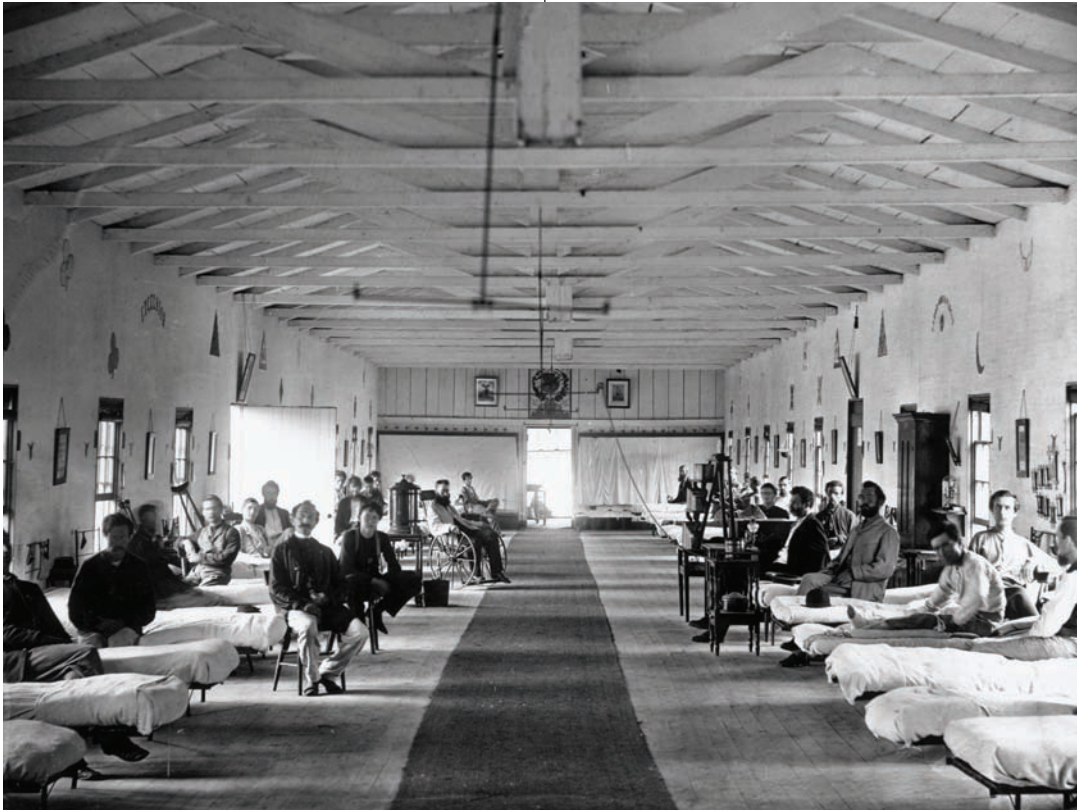### Anatomical Apparitions

**1>>** At least 90 percent of amputees have had a phantom limb: they perceive that a missing body part is still present and attached to their body. Such phantoms are often very painful and may persist for years.

**2>>** Recent studies suggest that phantom limbs are not the product of erroneous neural signals emanating from an amputee's stump. Rather they are now thought to arise largely from activity in neural networks in the brain that build a mental image of the body.

**3>>** Researchers are trying to treat phantom limb syndrome using mirrors and virtual reality, both of which create illusions that can help patients gain better control over their ghostly appendages and may help decrease phantom pain.

Phantom limbs sometimes perform phantom movements—but in other cases they are paralyzed.



Armory Square Hospital, Washington, D.C., 1865. American neurologist Silas Weir Mitchell coined the term “phantom limb” to describe the sensations that Civil War soldiers felt in their lost limbs.

tions can occur in any excised body part, not just the arms and legs; people who have lost their breasts, teeth, genitals and even internal organs have had them. Women with hysterectomies, for example, have felt illusory menstrual pain and laborlike uterine contractions.

Pain from phantom limbs can also be very debilitating. Amputees with such pain are much less likely to use a prosthetic limb, studies have shown, restricting their ability to care for themselves, visit friends and engage in other activities. And unfortunately, only a tiny fraction of such patients find relief from the dozens of available pain therapies.

### Blaming the Brain

Despite decades of investigation, scientists have not pinned down the biological origins of this disturbing illusion. An early notion, put forth during the second half of the 20th century, came from the late neuroscientist Patrick Wall, then at University College London. Wall placed blame for the phantom limb phenomenon on the severed nerve fibers in the scarred region of the

amputee’s stump. These fibers form nodules, or neuromas, which were thought to send erroneous signals through the spinal cord to the brain that might be misinterpreted as tingling or pain in the absent limb.

When doctors attempted to treat phantom limb sensations by cutting the sensory nerves leading to the spinal cord, severing nerves in the cord, or even removing parts of the brain that receive the sensory neuronal tracts, the phantoms nonetheless persisted. Sometimes the patients’ pain temporarily vanished but then returned. Thus, many researchers rejected the idea that problems with the peripheral nerves could fully account for the syndrome.

In the late 1980s psychologist Ronald Melzack of McGill University and his colleagues put forth the alternative notion that illusory body parts arise at least in part from neural activity within the brain. Such a view echoed earlier writings from naturalist Erasmus Darwin, an 18th-century British intellectual and grandfather to Charles Darwin, who once penned: “Does it not seem clear that such a [phantom]

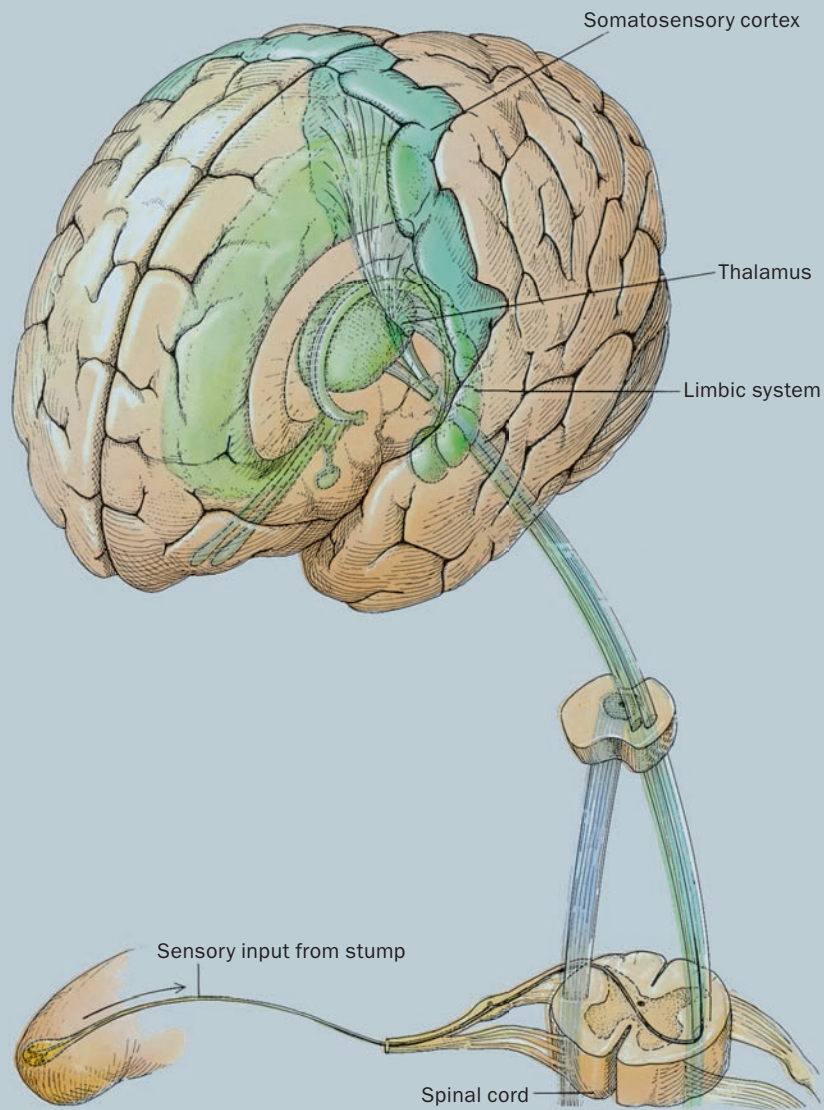
BETTMANN/CORBIS



## The Body in the Brain

The brain not only receives sensory signals from various parts of the body, but it is thought to generate its own pattern of neural activity that represents the body in its intact state. The brain's somatosensory cortex contains a map of various body regions; it receives tactile information from the body via a sensory

pathway that traverses the thalamus. Another neural conduit transmits information from the body to the limbic system, which governs emotions such as those associated with phantom limbs. After the loss of a body part, activity in this neural system may result in the perception of a phantom limb.



phenomenon indicates that our ideas and sensations emerge from our brains, and not from our tactile organs?”

In Melzack’s view, the brain not only detects sensory signals from the body but also generates its own neural pattern, or neural signature, that represents the body in its intact state. This signature inscribes the psyche with a sense of the

body’s configuration and borders—and of the body belonging to an individual. It persists even after the removal of a body part, creating the mistaken perception that the part is still present and attached to the body.

Orchestrating such a neural signature, the theory goes, falls to a large network of neurons that Melzack termed the “neuromatrix.” The

# The brain can create a **neural picture** of the human physique even without sensory signals from the body.

neuromatrix includes the somatosensory cortex at the brain's surface on the top of the head and other regions of the parietal lobe (a quadrant of the brain beneath the top and back of the head) that construct a person's body image and his or her sense of self. In addition, it consists of two neural pathways: the sensory pathway that conveys tactile information through the thalamus—a sensory relay station deep in the brain—to the somatosensory cortex and another that traverses the brain's limbic system, a group of buried brain structures that govern emotions such as those associated with phantom limbs [see box on opposite page].

Consistent with such a theory, damage to part of this neuromatrix can result in the loss of ownership of part or all of one's body. (It might also result in body integrity identity disorder [see "Amputee Envy," by Sabine Mueller, on page 60].) Injuries to the right parietal lobe caused by brain trauma or stroke can lead to left hemibody neglect syndrome, in which patients become indifferent to the entire left side of their body. Such patients may, for example, fail to put on the left sleeve of a shirt or a left shoe. When asked about such behavior, these individuals typically deny that the left arm or leg is theirs; the counterpart to the right side of their body, they assert, belongs to someone else.

The effect can be transient in some cases—and very strange. In one instance described to me, a NASA astronaut piloting his first space mission told his colleagues during the initial orbit to "stop poking their hands in his left control panel." His crew informed him that the hand in question was his own, but the pilot denied it, declaring that "the hand in the left panel is certainly not mine." A few hours later, to the relief of the crew (and Houston), the pilot suddenly said, "Just relax, guys. I have found my missing left hand on the control panel!" Presumably, the spacecraft's acceleration during liftoff or the lack of gravity temporarily deprived the pilot's right parietal lobe of blood, producing a fleeting form of left hemibody neglect syndrome.

## Modifying the Matrix

The basic structure of our neuromatrix may be present at birth, its blueprint likely inscribed in our genes, Melzack proposes. Such a congeni-



tal network would explain why, as Melzack and his colleagues reported in 1997, phantom arms or legs often appear in children born without these body parts. Melzack's team found phantoms in 41 of 125 people who were either born without a limb or had one amputated before age six, indicating that such anatomical ghosts occur in about a fifth of people missing a limb at birth and more than half of amputees who are young children. Thus, the human brain seems able to generate a neural picture of the complete human physique even in the absence of sensory signals from the body.

Nevertheless, gross changes in body structure after birth—and, consequently, neural input to the neuromatrix—can provoke changes in this brain network, some of which may buttress the brain's role in creating phantom limbs. The somatosensory cortex in the parietal lobe contains neurons that receive input from, and so are thought to produce a conscious sense of, the various body parts.

A vertical mirror reflecting the image of an intact limb can create the illusion that a phantom limb has been resurrected and can be controlled. Exercises using such a mirror have relieved phantom limb spasms and pain in a small number of amputees.

## (The Author)

MIGUEL NICOLELIS is a professor of neurobiology and biomedical engineering at Duke University and coordinator of the Edmond and Lily Safra International Institute of Neurosciences of Natal in Brazil. He also lectures at the Swiss Federal Institute of Technology in Lausanne, Switzerland. He holds an M.D. and a Ph.D. from the University of São Paulo.

An amputee immerses himself in a three-dimensional virtual reality in which his real limb movements are transposed onto a virtual limb that serves as a stand-in for his phantom limb. In this world, users transfer feelings from their real limb to the muscles and joints of the phantom. A preliminary study suggests that the illusion can result in partial relief of phantom pain.



These neurons are arranged in a topographical map. Experiments conducted in the 1980s by neuroscientists Jon Kaas of Vanderbilt University and Michael Merzenich of the University of California, San Francisco, and their colleagues, among others, have shown that am-

putation causes a restructuring of this body map such that the cerebral neurons that represented the excised part switch their allegiance to adjacent body regions. Merzenich's team, for example, found that amputation of a monkey's middle finger caused the brain cells that previously responded only to stimulation of that finger to respond instead to stimulation of the index and ring fingers within a matter of months.

In 1993 John Chapin and I showed that this reorganization process started immediately after blocking impulses from sensory nerves in the whiskers of rats and that it occurred in the thalamus, among other deeper brain structures, as well as the somatosensory cortex. The late neuroscientist Tim Pons, then at the National Institute of Mental Health, and his co-workers extended this idea. Cutting off sensory input from a monkey's entire arm, they found, prompted a more widespread reorganization in which the neurons once assigned to the hand switched to react to signals

from the face, which is represented next to the arm in the brain's map. In 1998 they reported a similar reorganization in the thalamus and brain stem relays of the somatosensory system.

Such revamping also occurs in the human cerebral cortex after an arm amputation, according to work by neuroscientist Vilayanur S. Ramachandran of the University of California, San Diego, and his colleagues. Using an imaging technique called magnetoencephalography, which measures the magnetic fields produced by electrical activity in the brain, the researchers showed in the early 1990s that sensory input from the face activated the hand area in the brain's cerebral body map.

When Ramachandran's team touched the faces of amputees in particular locations, the researchers found that the sensory nerve signals, now traveling to the hand area of the somatosensory cortex, evoked feelings in their phantom hand. Moreover, the researchers found that the lower face region contains an organized map of the hand such that tactile stimulation of specific points on the face elicits sensations from specific points on the phantom hand. The type of sensation—whether hot, cold, rubbing or massage—is the same in both locations.

Other efforts have since linked such brain reorganization to phantom limb pain. In a 1995 study neuroscientist Herta Flor of the University of Heidelberg in Germany and her colleagues used noninvasive neuromagnetic techniques to detect the degree of cortical reorganization in 20 amputees. They found a strong relation between the amount of neural restructuring and the magnitude of phantom arm pain, suggesting that the pain may result from such changes in the somatosensory cortex.

A follow-up 2001 study led by psychologist Niels Birbaumer of the University of Tuebingen in Germany lends further support to this idea. The scientists, who included Flor, used a brain-imaging technique called functional magnetic resonance imaging to show that imagined movement of the phantom hand activated the face area of the somatosensory cortex in patients with phantom limb pain, but not in pain-free amputees. The researchers hypothesize that phantom limb pain results from the simultaneous activation of the hand and mouth regions of the brain's body map.

### Ghost Busters

Ramachandran and his wife, neuroscientist Diane Rogers-Ramachandran, have since developed a possible treatment for phantom limb syn-

COURTESY OF STEVE PETTIFER



# Researchers are trying to ameliorate phantom limb pain using computer simulations of the body.

drome based on the malleability of the brain's body maps. The researchers removed the top of a cardboard box and inserted a vertical mirror. Ten arm amputees inserted their intact arm in the front of the box so that the arm's reflection in the mirror overlay the perceived location of the phantom limb. This created a visual illusion that the phantom arm had been resurrected. When each patient moved his real arm, he could see that his "phantom" arm was obeying his motor commands [see "It's All Done with Mirrors," by Vilayanur S. Ramachandran and Diane Rogers-Ramachandran; SCIENTIFIC AMERICAN MIND, August/September 2007].

Six of the patients who used the mirror box said they could feel as well as see their phantom moving, generating the impression that both arms could now be moved. Four of the patients used this newfound ability to relax and open a clenched phantom hand, which provided relief from painful spasms. Three weeks of daily practice with the mirror caused one patient's phantom arm to largely disappear. And when most of the limb vanished, so did the pain from the phantom elbow. The visual illusion apparently corrected the tactile one, suggesting that the activity of central visual circuits can modify the activity of the proposed neuromatrix, the researchers reported in 1996.

A decade later psychologist Eric Brodie of Glasgow Caledonian University in Scotland and his colleagues reported hints of success in a test of a mirror box modified for a leg. Forty-one lower-limb amputees watched a reflection of their intact leg in the mirror as they moved this leg and tried to move their phantom leg. Another 39 amputees tried to move both their phantom and real legs without the mirror. Both efforts, which involved 10 different movements each repeated 10 times, diminished phantom limb sensations, including pain. Although the mirror did not enhance this effect, it did produce significantly more phantom limb movements and more vivid awareness of the phantom leg than did the exercise without the mirror. Prolonged mirror treatment might be more effective in fighting phantom pain, the researchers propose, perhaps by reversing the ongoing reorganization of the brain thought to be responsible for phantom limb pain.

Researchers are now trying to ameliorate

phantom limb pain with immersive three-dimensional computer simulations—so-called virtual reality (VR)—that can produce illusions similar to those created by the mirror. The technology can display a patient's entire body, including his or her phantom limb, and enable the patient to perform complex movements of the fingers, toes, hands, feet, arms and legs that are not possible with mirror therapy. In a preliminary 2007 study psychologist Craig Murray and his colleagues at the University of Manchester in England exposed two upper-limb amputees and one lower-limb amputee to a simulation that transported a user's limb movements to those of a virtual limb, which overlay their phantom limb in the virtual environment. All three amputees, who participated in two to five VR sessions, reported that sensations from their real limb were transferred to the muscles and joints of their phantom limb. In each case, phantom pain decreased during at least one of the sessions, suggesting that such therapy might offer pain relief for these types of patients.

The possibility of such a treatment seemed remote that afternoon in São Paulo, some 25 years ago, when I saw the boy shrieking in pain from a leg he no longer had. If I had known then what I know now, I would have been able to reassure the boy that what he was feeling, however excruciating and strange, was merely a phantasmagoric tactile memory of the past, created in every exquisite and cruel detail by a normally functioning brain—and not by a terrible curse. Perhaps by knowing that, my first patient would have found more bearable such a frightening and undesirable life companion. **M**

## (Further Reading)

- ◆ **The Perception of Phantom Limbs: The D. O. Hebb Lecture.** V. S. Ramachandran and William Hirstein in *Brain*, Vol. 121, Part 9, pages 1603–1630; 1998.
- ◆ **Analgesia through the Looking Glass? A Randomized Controlled Trial Investigating the Effect of Viewing a "Virtual" Limb upon Phantom Limb Pain, Sensation and Movement.** Eric E. Brodie, Anne Whyte and Catherine A. Niven in *European Journal of Pain*, Vol. 11, No. 4, pages 428–436; published online July 20, 2006.
- ◆ **Phantom Limbs.** Ronald Melzack in *Scientific American Reports*, Vol. 16, No. 3, pages 53–59; September 2006.
- ◆ For information about amputation, see [www.answers.com/topic/amputation-3?cat=health](http://www.answers.com/topic/amputation-3?cat=health)